

A Comparison between Scaling and Root Planning (SRP), antibiotic and diode Laser application in treatment of Localized Juvenile periodontitis (Microscopical Study)

Muhammed I. Hazeem*

College of Dentistry, Tikreet University, Iraq.

* Corresponding author: Muhammed I. Hazeem; e-mail: mohamedalhazeem@tu.iq

Received: 12 April 2017

Accepted: 04 May 2017

Online: 12 May 2017

ABSTRACT

The present study aimed to study different ways for treatment of Localized Juvenile periodontitis, cultural and microscopic results of specimens from base line, appeared the following bacterial strains: *Bacteroides gracilis*, *Fusobacterium nuclautum*, *Porphyromonas intermedia*, *Actinomyces*, *peptostreptococcus species*, *eikenella corrodens*, *streptococcus intermedius*, *Streptococcus salivaris*. Which distribution in 50% gram positive and 50% gram negative. Cultural and microscopical result after ten days of the experimental design appeared significant difference $P \geq 0.05$, at the SRP group results of microscopic and culturing show *Peptostreptococcus species*, *Prevotella intermedia*, *Fusobacterium nuclautum*, *Streptococcus Salivaris*. While at the SRP and antibiotic treated group (Doxycyclin 100 mg) the pattern of microbial study appeared the following bacteria: *Fusobacterium nucleotum*, *Peptostreptococcus*, *Streptococcus salivaris*. At the other hand the results of third group SRP and diode Laser appeared no growth of microorganism at all site subjected to Laser 0.8 w, 940 nm for 20 sec after ten days of study.

Keywords: Localized Juvenile periodontitis, Diode laser, pathogenic bacteria.

1. INTRODUCTION

Localized Juvenile periodontitis occurs in children and young adults and can be classified into: periodontitis which occurs in otherwise healthy individuals, and periodontitis which occurs in juveniles with systemic disease [1]. The periodontitis which occurs in otherwise healthy individuals consists of two major forms: juvenile periodontitis, also called periodontosis or localized juvenile periodontitis (LJP), and generalized juvenile periodontitis which includes early onset adult periodontitis, recurrent necrotizing ulcerative periodontitis and the true generalized form of juvenile periodontitis [2]. A major infecting organism, *Actinobacillus actinomycetemcomitans*, is strongly associated with the disease, and may be an exogenous pathogen since it is not found in healthy individuals or in healthy sites in LJP patients [3]. It is

virulent with marked aggressive properties and it induces a marked antibody response in infected patients. Eradication of *Actinobacillus actinomycetemcomitans* requires attention to the fact that it invades the tissue and hence systemic antimicrobials or surgical excision of the tissues is necessary for eradication [1,2,4]. Marked suppression of the organism from sub gingival sites is associated with healing. Treatment Periodontal Therapy through several ways Scaling, Root planning, Bone Graft and Debridement [5]. Diode Laser also used in periodontal therapy its effect in Pain Relief through blocks the pain signals transmitted from injured parts of the body to brain, this decrease nerve sensitivity[6]. Inflammation reduction by causes the smaller arteries and lymph vessels of the body to increase in size- called

Vasodilatation which allows Inflammation, swelling and edema to clear away from injury site. Also Promotes lymphatic drainage which also aids in this vital healing process [7,8]. Accelerate tissue Repair when Photons of light emitted by therapeutic laser penetrate deeply in to the tissues of the body to stimulate the production centers of individual cells. And Cell Growth, wound healing by increase the formation of new capillaries (tiny blood vessels) within damage tissue [9]. And Reduce formation of Scar tissue, by speeding up the healing process, improving the blood flow to injured area and Carry away waste products fast heading always lead to less scar formation [1, 3].

2. MATERIALS AND METHODS

From June, till November, 2016, samples were taken from different female have no history of systemic disease and they are not taken any antibiotic for 6 month ago nor visit a dentist. complain of Localized Juvenile periodontitis, a disease characterized by true pocket formation and mobility of permanent upper and lower centrals and first molars, the mean age 10 years old , admitted to the periodontic department, teaching hospital at collage of dentistry, Tikrit University , The study includes a total of 15 cases (from each patients 4 site, when the total site represented in the study reach to 60 site).

Patients were divided in to 3 groups: - Test group(1) 5 patients and 20 sites ,anterior and posterior teeth included, only scaling and root planning had been done by curettes . The patients in this group teaching the correct use of tooth brush and using of dental floss. No mouth wash has been prescribed. Test group (2) also 5 patients and 20 sites ,deep scaling and root planning and Doxycycline 100 mg for 10 days 1x2 . Test group

(3) scaling and root planning, diode laser application 940 nm, 0.8 W. for 20 sec. for 5 patients and 20 sites. At base line, supra-gingival scaling and polishing had been done for all patients, in three groups, to eliminate and get rid of supra-gingival plaque and biofilm which are not needed in this study, then for all patients, subgingival sampling had been done by separating the affected teeth by cotton roll and dries it by air syringe. A size 30 paper point inserted deeply inside the pocket for about 10 seconds and then subjected for culturing examination when all samples were inoculated on suitable culture media blood agar, (Himedia/India), and chocolate agar and examined in the anaerobic gas pag, for identification, differentiation and confirmation of bacteria from specimens and incubated for 24 Hrs at 37 °C [10].

2.1 Statistical Analysis

The Statistical Analysis System-SAS (2012) was used to determine the effect of type of treatment in inhibition growth rate in the studied female. Least significant difference–LSD test was used to compare the significance between means of obtained result [11].

3. RESULTS AND DISCUSSION

The specimens used in present study were obtained from different female cases. The enrolled cases included after directly inoculated onto plates of blood agar and chocolate agar incubated at 37°C for 24 h, of 60 total specimens from base line, the cultural and microscopic results appeared the following bacterial strains: *Bacteroides gracilis*, *Fusobacterium nuclautum*, *Porphyromonas intermedia*, *Actinomyces, peptostreptococcus species, eikenella corrodens, streptococcus intermedius, Stoeptococcus salivaris*. Which distribution in 50% gram positive and 50% gram negative as show in figure (1).

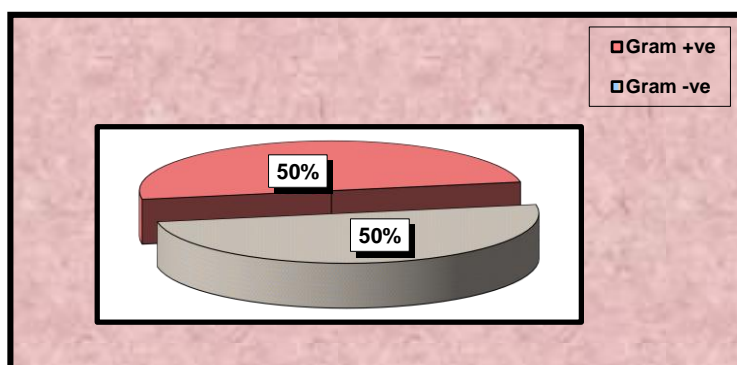


Figure 1: Percentage of Gram +ve & Gram -ve Isolates in The Present Study at base line.

Cultural and microscopical result after ten days of the experimental design appeared significant difference $P \geq 0.05$, at the SRP group results of microscopic and culturing show *Peptostreptococcus species, Prevotella intermedia, Fusobacterium nuclautum, Streptococcus Saliveris*, The analysis considered the role of scaling and planning in the management of the condition. This accepted treatment, however, was considered insufficient, as evidenced by the plethora of studies

exploring adjunct treatments these functions clarified the meaning of periodontal disease as an indicator of changes in the immune system. Similar changes had been observed leading to chronic diseases [12]. Pursuit of this newer approach could result in significant changes in management of periodontal disease as well as offer insights into associated chronic diseases. While at the SRP+AB treated group the pattern of microbial study appeared the following bacteria: *Fusobacterium*

nucleotum, *Peptostreptococcus*, *Stoeptococcus salivaris*[13]. Doxycycline (Doxy) had the potential to inhibit the periodontopathogenic bacterial proteinases, which contribute to tissue destruction cascades during periodontitis directly and indirectly by triggering the host response[12]. They studied the effects of Doxy on proteolytic, serpinolytic, and progelatinase-B activation activities of potent periodontopathogens. They found that Doxy inhibited the degradation of human serum albumin by cells of *P. gingivalis* and *T. denticola* and also inhibited the inactivation of alpha1-proteinase inhibitor (serpinolytic activity) by a collagenolytic fraction of *P. gingivalis* [4].

Etiology of Localized Juvenile periodontitis (LJP) *Actinobacillus actinomycetemcomitans* (A.a) are the most commonly found bacteria others like *P. Gingivalis* , *E.Corrodens* , and Spirochetes which produce Leukotoxins, Collagenase and Bone resorbing factors that leads to bone destruction. incidence of *Actinobacillus* is greater in younger patients than in older one [14]. The most clinical features was onset around the time of puberty, occur in otherwise healthy individual, localized almost exclusively in incisors and molars (upper and lower permanent incisors and

molar), also more in females, more in blacks, finally abnormality in phagocyte function. To treatment of this case the patients should early diagnosis and extraction (according to case severity) and using specific antibiotics like Tetracycline, and Doxycycline capsule 100 mg given 1x2 .. Mechanism of doxycycline action done through inhibit bacterial protein synthesis and can inhibit mammalian collagenases and others matrix metalloproteinase (MMPS) by a mechanism independent of their antimicrobial activity, examples of the clinical potential of this no antimicrobial property of tetracycline's the treatment of periodontal diseases and others medical disease [15].

At the other hand the results of third group SRP+ diode laser appeared no growth of microorganism at all site subjected to laser 0.8 w, 940 nm for 20 sec after ten days of study as show in table (1), laser assisted periodontal therapy was performed using a diode laser above the base of the pocket using a sweeping motion for approximately 20 seconds per site, with care taken to keep the tip free from debris to avoid initiation [16]. The bacterial strains distributed according to gram stain as summarized in table 2.

Table 1: Microscopical and cultural results of the three studied group after three weeks.

Studied Group	Results of Microscopic and Culturing
SRP	<i>Peptostreptoccal species</i> , <i>Prevotella intermedia</i> , <i>Fusobacterium nuclautum</i> . <i>Strept Saliveris</i>
SRP+AB	<i>Fusobacterium nucleotum</i> , <i>Peptostreptococcus</i> , <i>Stoeptococcus salivaris</i> .
SRP+ diode Laser	No microbial results

Table 2: Results of distribution Bacterial Isolates according to gram stain.

Bacterial Isolates	Gram stain
<i>Peptostreptoccal species</i>	Gram positive
<i>Prevotella intermedia</i>	Gram negative
<i>Fusobacterium nuclautum</i>	Gram negative
<i>Strept Saliveris</i>	Gram positive
<i>Fusobacterium nucleotum</i> .	Gram negative
<i>Peptostreptococcus bacteria</i>	Gram negative
<i>Stoeptococcus salivaris</i>	Gram positive

These variable morphologies of bacterial isolates in the studied groups suggested the distribution based on the way of treatment in the studied group SRP , SRP+AB and SRP+ diode Laser presence of many different species related to the same female may be related to the immunological state and also the way of using of antibiotic in the experiment at the other hands SRP+ diode Laser group showed no microbial growth, this results may be attributed to the high activity of diode laser 0.8 w, 940 nm for 20 sec.

The diode laser may have potential as an adjunctive therapy, but support for that view based on the scientific evidence is equivocal and remains controversial [17]. Outcomes of studies are varied and often conflicting in terms of efficacy. This present results

identifies possible mechanisms that could have contributed to this issue: tissue response to laser therapy was demonstrated to be dependent on tissue type and health, and the successful therapeutic treatment window was shown to be specific to the target tissue and prevent the growth of pathogenic microorganism, mechanism by which diode laser also used in periodontal therapy its effect in pain relief through blocks the pain signals transmitted from injured parts of the body to brain ,this decrease nerve sensitivity [18]. Inflammation reduction by causes the smaller arteries and lymph vessels of the body to increase in size- called Vasodilatation which allows Inflammation, swelling and edema to clear away from injury site. Also promotes lymphatic drainage which also aids in this vital healing process. Accelerate tissue

repair when photons of light emitted by therapeutic laser penetrate deeply in to the tissues of the body to stimulate the production centers of individual cells [16].

4. CONCLUSION

In summary, whereas no Study in Salahaldeen governorate in Iraq about the role of diode laser in the treatment of Localized Juvenile periodontitis , present study to the female showed effective role in remove the growth of microbial pathogenic and its better than studied group in subjected study.

5. REFERENCES

1. Kuboniwa M, Tribble GD, James CE, Kilic AO, Tao L, Herzberg MC, Shizukuishi S, Lamont RJ. *Streptococcus gordonii* utilizes several distinct gene functions to recruit *Porphyromonas gingivalis* into a mixed community. Mol Microbiol 2006; 60:121-39
2. Daep CA, Novak EA, Lamont RJ, Demuth DR. Structural dissection and in vivo effectiveness of a peptide inhibitor of *Porphyromonas gingivalis* adherence to *Streptococcus gordonii*. Infect Immun 2011;79:67-74
3. Wright CJ, Wu H, Melander RJ, Melander C, Lamont RJ. Disruption of heterotypic community development by *Porphyromonas gingivalis* with small molecule inhibitors. Mol Oral Microbiol 2014.
4. Page RC, Schroeder HE. Periodontitis in man and other animals—a comparative review. Basel, Switzerland: Karger; 2015
5. Ramsey MM, Rumbaugh KP, Whiteley M. Metabolite cross-feeding enhances virulence in a model polymicrobial infection. PLOS Pathog 2011; 7:e1002012
6. Stacy A, Everett J, Jorth P, Trivedi U, Rumbaugh KP, Whiteley M. Bacterial fight-and-flight responses enhance virulence in a polymicrobial infection. Proc Natl Acad Sci U S A 2014; 111:7819-24
7. Hajishengallis G. Immunomicrobial pathogenesis of periodontitis: keystones, pathobionts, and host response. Trends Immunol 2014; 35:3-11
8. Hajishengallis G, Lamont RJ. Beyond the red complex and into more complexity: The Polymicrobial Synergy and Dysbiosis (PSD) model of periodontal disease etiology. Mol Oral Microbiol 2012; 27:409-19
9. Knights D, Lassen KG, Xavier RJ. Advances in inflammatory bowel disease pathogenesis: linking host genetics and the microbiome. Gut 2013; 62:1505-10
10. Jacobsson G., Invasive Staphylococcus aureus infections, Sahlgrenska Academy University of Gothenburg, Sweden, 2009.
11. SAS users(2004). Guide personal computer (ver.7) inst. Inc. Cary. Nc. USA.
12. Jorth P, Turner KH, Gumus P, Nizam N, Buduneli N, Whiteley M. Metatranscriptomics of the human oral microbiome during health and disease. MBio 2014; 5:e01012-14
13. Page RC, Schroeder HE. Periodontitis in man and other animals—a comparative review. Basel, Switzerland: Karger; 1982.
14. Nell S, Suerbaum S, Josenhans C. The impact of the microbiota on the pathogenesis of IBD: lessons from mouse infection models. Nat Rev Microbiol 2010; 8:564-77
15. Hajishengallis G, Liang S, Payne MA, Hashim A, Jotwani R, Eskin MA, McIntosh ML, Alsam A, Kirkwood KL, Lambris JD, et al. Low-abundance biofilm species orchestrates inflammatory periodontal disease through the commensal microbiota and complement. Cell Host Microbe 2011; 10:497-506
16. Hajishengallis G, Lamont RJ. Breaking bad: manipulation of the host response by *Porphyromonas gingivalis*. Eur J Immunol 2014; 44:328-38
17. Jiao Y, Darzi Y, Tawaratsumida K, Marchesan JT, Hasegawa M, Moon H, Chen GY, Nunez G, Giannobile WV, Raes J, et al. Induction of bone loss by pathobiont-mediated nod1 signaling in the oral cavity. Cell Host Microbe 2013; 13:595-601
18. Pirnat. (2007). Versatility of an 810 nm diode laser in dentistry: an overview. Journal of Laser and Health Academy, No. 4.

© 2017; AIZEON Publishers; All Rights Reserved

This is an Open Access article distributed under the terms of the Creative Commons Attribution License which permits unrestricted use, distribution, and reproduction in any medium, provided the original work is properly cited.
